

Review article

Surgical treatment of hernia in cattle: A review

Rafid H. Farman¹ Saad Hashim Al-Husseiny² Ali Nair Abd Al-Ameer³

¹Department of surgery and obstetrics College of Veterinary Medicine, University of Al-Qadisiyah, Iraq

²Department of internal and preventive medicine, College of Veterinary Medicine, University of Al-Qadisiyah, Iraq

³Private sector, Iraq

Corresponding Author Email: rafid.farman@qu.edu.iq

Co-Author Email: Saad.ghmeiss@qu.edu.iq

(Received 5/8/2017, Accepted 18/11/2017)

Abstract

This study aimed to highlight on hernial types that effect animals specially in cattle, the ways of diagnosis and treatment by using different techniques, which way is more suitable either the highlight on advantage and disadvantage of these techniques. There are many type of hernia may happen in cattle's but the most frequently noted in cattle was ventral and umbilical hernia. The researches confirmed that the umbilical hernia usually accrued in calves due to failure to close of the umbilical cord, while ventral hernia is usually present in cattle due to trauma, heavy weight. Hernia was easy to diagnoses by case history, inspection and palpation. There are several techniques to treat hernia, surgical or non-surgical depending on the size and the type of hernia. In case of surgical techniques, there are two-type open and closed surgical operation. The recent searches commend that in case of simple and small hernia in size they treat by suturing the edges of ring by absorbable suture (Hernioraphy), but in case of large hernia must be used mesh to support the muscle in technique named (Hernioplasty). Mesh may cause irritation in its site, cause post-operative pain, and delay the time of healing so the recent searches to make solution to this problems mesh must be covert by special material to make barrier between it and muscle and lubricated the site hernia.

Key words: Hernia, Cattle, Hernioraphy, Hernioplasty, Mesh

Introduction

Hernia:

Hernia is a bulge of skin contain material of a body cavity pass through a weak spot of the body wall. This possibly will occur by accident or due to normal anatomical opening, which does not completely fulfill its functional (1).

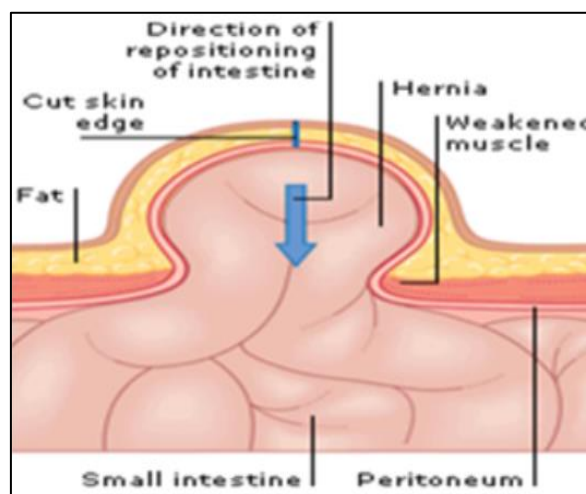


Figure (1): General shape of hernia (W.W.W.Aviva.Co.Uk).

Anatomically Hernia consists of three parts, Hernial Ring, Hernial Sac and Contents. (2). In cattle's most common site of a hernia is the abdominal wall which consists of the muscles and ligaments, which act as shield and the natural function of it carrying the abdominal contents mainly the intestines. When any weakness extend in the abdominal wall, the shield loses his job and form a hole which called hernial ring, then part of the viscera of the abdominal cavity pass through the hole and then bulging which is visible on the skin as a hernia (3). The hernia either occur when there is a natural weakness in the inguinal canal and femoral or the umbilicus area caused wide in these canal and passing of viscera through it (4). A primary diagnosis was made from the history and by palpation of the hernial region. Diagnosis of the cases, however, it is confirm by exploratory puncture of the swelling and demonstration of intestinal contents. (5). There are several way to surgical treatment of hernia which depended the size of hernial ring at the site, primary repair (Hernioraphy) a surgical treatment of simple hernia complete with sutures sited in a straight line in the abdomen, mesh repair (Hernioplasty) surgical repair, of large and complex hernia by using networks and may be use a laparoscope(6). Complex abdominal wall and hernia treatment uses a mixture of primary and mesh (7).

The Types of Hernia:

1-Reducible Hernia: In this type can be manually or automatically return the hernial contents into the abdominal cavity.

2-Irreducible Hernia: in this type, the hernial contents cannot be return into the abdominal cavity. Therefore, the complication of this type (8).

Types of Hernia Depending on its Location

Umbilical Hernia:

Umbilical hernia have been described as heredity in all species of animals, in cattle most of them are small, so the defected

animals should not be used as breeding animals. They most commonly occur in Holstein-Friesian cattle, with heifer calves being at greater risk than bull calves. Congenital hernias outcome from closure of the peritonea but an inadequate closure of the body wall round the umbilicus causing protrusion of the peritoneum through fascia and skin (9). Umbilical hernias in calves generally current in veterinary, which are causing due to failure of the normal closure of the umbilical ring, and which result in the projection of abdominal contents into the overlying subcutaneous.either may happens when cutting the umbilical cord near the body or when animals chewed the umbilical cord, or may be happened due to contaminated handling with the umbilical cord during caesarean section, leading to Omphalitis and weaknesses making them convertible to hernia (4, 10). .

Inguinal Hernia:

Inguinal hernias are heredity or acquired and they have not been described in the cow or ewe (9). Which is result due to drooping abdominal viscera through a defect in the inguinal channel when animal be aged or extreme stress. In this type of hernia, part of the bowel may slip through the inner ring to the inguinal canal. It is common in males, as well as we can use X-rays to diagnose (11).

Scrotal Hernia:

The hernia marks as extension of the inguinal hernia when viscera reaching to scrotum through the internal and external Inguinal canal. The causes of this type of hernia be genetic or acquired, so it is best to hold castration process Castration of defected animals (12). In addition to diagnosis of scrotal hernia in sheep and goats, physical examination, plain or contrast radiography and trans-scrotal ultrasonography can be used to this purpose (13).

Femoral Hernia:

Drooping part of the intestine through the passing region of the femoral vein and artery from the abdomen to the femora, and the fact that the area where gets hernia. This canal called the femoral canal. Diagnosis is this

hernia by making the animal standing on hind limbs and feel the bulging ventrally to inguinal ligament and laterally to Pelvic brim (4).

Incisional Hernia:

This type happen, when ancient abdominal surgery has debilitated the abdominal wall or may cause infection at the surgical site causes a collapse of the wound closure (14). So septic wounds after the operation, which is the most dangerous predisposing factor and metabolic disorders such as weight gain and kidney deficit, diabetes, lack of protein or vitamin C and the use of some treatments, such as steroids and chemotherapy in addition to the increase in intra-abdominal pressure and Reform manner tensile accompanied by a high percentage hernia (15,16).

Perineal Hernia:

This type of hernia is different from other types that the contents of the hernia doesn't covered by peritoneum, and partly due to the weakness of muscle of perineum making it easier to droop some viscera of the abdominal and pelvic cavity. Usually in Perineal hernia animal has abdominal swelling and brutal space director and in some cases bilateral in perineal area is swollen (17, 18). Contrast studies, either positive or negative, may be helpful and it may have an abdominal shape in a perineal hernia (8).

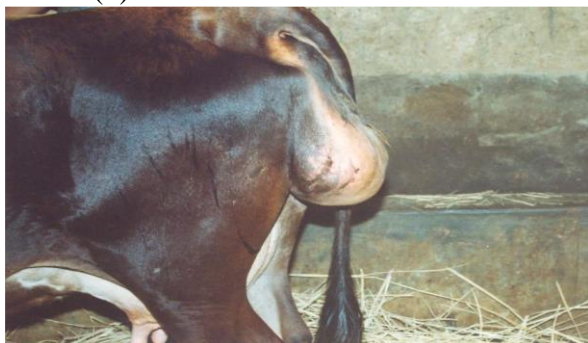

Figure. (2): Show the Perineal hernia (18).

Treatment of Hernia:

Type of surgical treatment of hernia

1- A primary repair (Hernioraphy) a surgical repair of simple hernia done by suturing the site of the abdomen.

Ventral Hernia:

A ventral hernia happens when the intestines project through the abdominal wall. Ventral hernia occurs as a result of external forces or trauma to abdominal wall, weakening of the abdominal musculature or rupture of preputic tendon It is commonly seen along the costal arch, (3).The diagnoses of the hernia made through the contents of the hernia and hernia ring be clear or palpated the viscera under the skin, but the diagnosis of Irreducible hernias defaulted and needed to use the X-ray to reflect the lack of abdominal wall continuity (19, 13). Exploratory laparotomy used to diagnosis the defect, X ray used to differentiate abdominal wall hernias from fibrino-cystic, abscess, and inflammatory swellings in bovine animals (20, 21).

Diaphragmatic Hernia:

Diaphragmatic hernia could be congenital or acquired. There seem to be few archives of congenital defects in horses. Diaphragmatic hernias are not seen clearly and it must be expected that such natural defects are very rare in the horse. Accidental rupture usually occurs from abdominal defect, following blunt wound or penetrating injuries to the abdomen cavity and chest. Frequently the clinical results at presentation include tiredness, respiratory complications and exercise intolerance (22).The most signs are tympany, depression, dullness and scanty feces. Reticulum of all animal with diaphragmatic hernia was locate at the 4th/5th intercostal space by ultrasonography (23, 24). Laparoscopically can be provided or could be used as a therapeutic technique according to the size and location of the defect. Necropsy or slaughter used to diagnosis of diaphragmatic hernias (25).

2- Repair by mesh (Hernioplasty) surgical repair, of large and complex hernia by using networks and may be using a laparoscope (6).

3- A combination of primary and mesh techniques are used to gather in compounding cases. Other types of complex repairs can include use of tissue extension, transfer, and even transplantation. Surgical time, duration of hospitalization, and postoperative complications may be reduced by using this technique of primary repair and avoiding mesh implantation (7).

Surgical Treatment of Hernia:

Control and Anesthesia:

The animals food and water intake should be reduced for 4 to 5 days and food completely stopped for 24 hours prior to surgery, controlled in dorsal oblique recumbency in case of ventral and umbilical hernia, Local anesthetic is infiltrated at the site of incision, xylazine hydrochloride can be improved as sedative combined with bupivacaine hydrochloride as a local painkiller for longer duration (26, 27).

Surgical Technique:

The technique of repair in umbilical hernia is same as for ventral hernia.

- 1-Two elliptical incisions are made through the skin on each side of the sac and are joined at each end, the hernia ring is adequately exposed.
- 2-The patch of skin between the incisions is bluntly dissected from the peritoneal sac and discarded.
- 3-The edges of the skin are reflected from the sac by blunt dissection.
- 4-The peritoneal sac is carefully dissected from the underlying tissue. Care should be taken to avoid severing the sac and exposing the peritoneal cavity.
- 5-The hernia is reduced by pushing the sac into the peritoneal cavity.
- 6-The hernia ring is closed by overlapping sutures using chromic catgut with umbilical tape in case of large ring. the edge of the ring along with fascia are fixed to the body wall with a simple continuous suture using chromic catgut.
- 7-The skin edge are suturing by interrupted sutures using non-absorbable suture material (2).

Using of Mesh:

Mesh is used to treat complex abdominal hernia with extensive tension produced along the incision of the abdominal muscle. The mesh is sited beneath the muscle. Although, use of non-absorbable synthetic mesh material to achieve a tension free closure of these abdominal wall defects is the most widely used reconstruction technique. Nylon mesh may be used for the repair of large abdominal hernias with adequate strength in adult bovines as an economic alternative to the costly meshes (3). The surgical adhesives that using for mesh fixation in hernia repair must be less traumatic to induce less tissue damage and less postoperative pain (28). So gel-like film shield the mesh to delay the adhesion between mesh and sorrowing tissue (29). In addition, collagen isolated from bovine fetal was set up to effectually support component repairs process including rapid re vascularization and extracellular matrix remodeling (30).

Types of Mesh:

1-Synthetic Mesh: prepared of nylon.

2-Biologic Mesh: They originate from the human cadavers skin or porcine (pig), bovine (cow) sources. They are more resist the infection and they stimulate growth of tissue (3).

Treated of Umbilical Hernias:

Umbilical hernias, usually small and easily reducible when uncomplicated and smaller hernias may spontaneously resolve (9). Surgical repair specified for hernias when the diameter of the ring more than 3 cm. there are many way of restoration have been used. Open reduction by increasing wound size, considered a result high tension and causing vascular compromise at the surgical site, while Simple apposition was considered faster to healing. In large defects (greater than 10 cm) may need mesh in its place (4, 31). Both the absorbable or non-absorbable materials were used to treat the umbilical hernioraphy. Absorbable sutures were used reasonably for young calves, while non-absorbable material used with elder calves to rise protection (1).

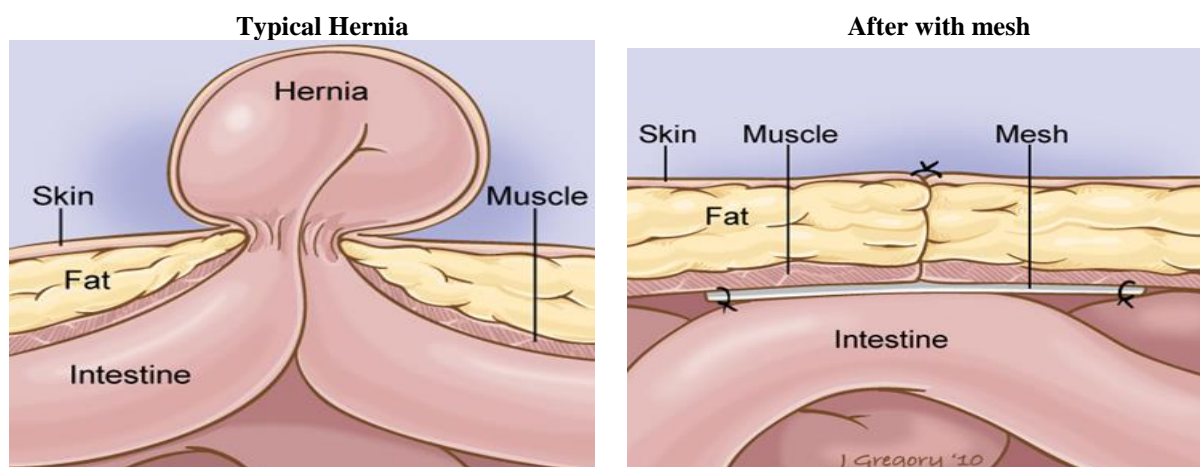


Figure (3): Treated of Umbilical hernias by Hernioraphy way by mesh (w.w.w.Cochranlaw.com).

Treatment of Ventral Hernia:

Abdominal hernias have been documented to have good surgical wound healing. However, in some complicated cases presents with poor prognosis. Like adhesions, intestinal incarceration. Diffuse fibrino-purulent peritonitis associated with ventral abdominal hernia in some cases and can be fatal even with proper patient stabilization (32).in Laparoscopic Ventral Hernia Repair (LVHR), adhesions are a common occurrence due to trauma of surgery or by the reaction of mesh or fixation devices. All techniques or devices create adhesions in site of hernia. This risk is prevent by use of films or meshes made of polyvinyl di fluoride (PVDF), Polypropylene, polyester coated by another material, like titanium, polydioxanon, cellulose, hyaluronic acid, or collagen (33, 34).

Treatment of Inguinal Hernias:

Inguinal hernias can repair by restoration the base of inguinal canal, this technique is difficult and being more inclined to recurrence, as well as the use of networks therapy is widely (11). large vaginal rings may be cause inguinal hernia. So, laparoscopic procedure, castration has been used to treat hernia when the animal not used for reproduction or in case of testicular damage (35). Reappearance of hernia may simply be prevented by closure of the vaginal ring using staples during castration by inguinal approach. (26, 36, 37).

Treatment of Scrotal Hernia:

Surgical repair of scrotal hernia provides satisfactory treatment (12, 38), with good, uncomplicated healing. Unilateral orchiectomy of an affected testicle is recommended for the preservation of the reproductive function of the contralateral non-affected testicle (38), as well as for the prevention of re herniation or seroma formation. Postoperative care should include careful monitoring by contrast radiography (39).

Conclusions

The conclusions of this study depending on previous studies are:

- 1-Umbilical hernias in calves usually find in veterinary due to failure to closed of the umbilical cord, while ventral hernia are commonly present in cattle due to trauma, heavy weight.
- 2-Hernioraphy technique used to treat simple hernia done with suturing the site of defect. While mesh repair (Hernioplasty) technique used to treat, a large and complex hernia by using networks and may be using a laparoscope.
- 3-Biologic mesh more suitable than Synthetic mesh for Hernioplasty in cattle. In addition, the benefit of biologic meshes in Hernioplasty was the resistances the infection and they enhance tissue growth for healing of hernia.

References

- 1-Sutradhar BC, Hossain MF, Das BC, Kim G, Hossain MA. Comparison Between Open And Closed Methods Of Hernioraphy In Calves Affected With Umbilical Hernia. *J Vet Sci.*; (2009); 10(4): 343–347.
- 2-Amresh K. Surgery of Abdomen and Organs of Digestive System. In *Veterinary Surgical Technique*. Ch. (2009); 14.P.P 310-312.
- 3-Singh BA, Preethi KhO, Devi AK, Gangwar NK, Katiyar SS, Kale G, Patel H, Singh N. Ventral Abdominal Hernioplasty Using Nylon Mesh In A Cow. *Indian Vet. J.*, (2014); 91 (11): 93 – 94.
- 4-Kumar V, Kumar N, Gangwar AK, Saxena AC. Using A Cellular Aortic Matrix To Repair Umbilical Hernias Of Calves. *Aust Vet J.* (2013); 91(6):251-253.
- 5-Salim MD, Abul Hashim M, Juyena NS, Arafat YA, Dey RK, Bag A, Islam MS. Prevalence of Hernia And Evaluation Of Herniorrhaphy In Calves. *International Journal of Natural and Social Sciences*, (2015); 2(4): 35-43.
- 6-Demirkiran AE, Ozgun H, Balkaya M, Cevikel H, Culhaci N, Gurel M. Strangulated ventral hernia model in rats. *J. Investigative Surg.*, (2003); 16(2): 93-97.
- 7-Whitfield-Cargile CM, Rakestraw PC, Hardy JN, Cohen D, Davis BE. Comparison of Primary Closure Of Incisional Hernias In Horses With And Without The Use Of Prosthetic Mesh Support. *Equine Veterinary Journal*, (2011); 43 (39) 69-75.
- 8-Kealy KJ, Mcallistor H, Graham JP. The Abdomen. In *Diagnostic Radiology and Ultrasonography of the Dog and Cat*. Ch. (2011); 2 PP: 167-168.
- 9-Roberts SJ. Disease and Accident of the Gestation Period. In *Veterinary Obstetrics and Genital Disease*. (Theriogenology). Ch. (2004); 7, P.P:184 -185.
- 10-Westmore T. The Ins And Outs of Umbilical Hernias. *Dairy News*. Vol. (2014); 14, 10.
- 11-Osman D, Mustafa G, Nurullah B, Ziya C, Erhan A, Cemalettin C. Comparison of Kugel and Lichtenstein operation for inguinal hernia repair: Results of prospective randomized study. *World J. Surg.*, (2006); 30(3): 346-350.
- 12-Roberts SJ. Scrotal hernia in rams: A case report. *Cornell. Vet. J.*, (1988); 78(4): 351-352.
- 13-Abdin-bey MR, Ramadan RO. Retrospective study of hernias in goats. *Scient. J. King Faisal. Univ.*, (2001); 2(1): 77-88
- 14-Bower CE, Read CC, Kriby LW, Roth JS. Complications of laparoscopic incisional-ventral hernia repair. *Surg. Endosc.* (2004); 18(4): 672-675.
- 15-Yahchouchy E, Aura T, Picone O, Etienne J, Fingerhut A. Incisional hernias and related risk factors. *Digestive Surg.*, (2003); 20 (1): 3-9
- 16-Klinge U, Joachim C, Carsten J, Volker S. Incisional hernia: Open techniques. *World J. Surg.*, (2005); 29 (8):1066-1072.
- 17-Padilla RL, Martinez MA, Quijano OF, Valerio UJ. Tension-Free perineal hernioplasty. *Hernia*, (1999); 3 (4): 221-223.
- 18-Shridhar NB. Perineal Hernia in a Crossbred Cow and Its Surgical Management. *Indian J. Anim. Res.*, (2011); 45 (1): 73–74.
- 19-Lund EP, Bergenfeldt M, Burcharth F. Traumatic abdominal hernia caused by cough, presenting with intestinal obstruction. *Hernia*, (2004); 8 (4): 399-401.
- 20-Muggli E, Lesser M, Braun U, Nuss K. Herniation Of The Gravid Uterus Through A Mesoduodenal Defect And Concurrent Omental Hernia In A Cow. *Veterinary Surgery* (2014); 43: 91–94.
- 21-Kumar1 A, Mohindroo J, Sangwan V, Mahajan S, Singh K, Anand A, Saini NS. Ultrasonographic Evaluation of Massive Abdominal Wall Swellings in Cattle and Buffaloes. *Turkish Journal of Veterinary and Animal Sciences*, (2014); 38: 100-103.
- 22-De Schutter P, Maes L, Pardon B, Deprez P. Diaphragmatic Herniation As A Rare Cause Of Anterior Functional Stenosis In Cattle. *Vlaams Diergeneeskundig Tijdschrift*, (2011); 80 Permanente Vorming 69.
- 23-Abdelaal A, Shaimaa G, Ismail A, Gomaa M. Reticular Diaphragmatic Hernia in Egyptian Buffaloes: Clinical, Hemato-Biochemical and Ultrasonographic Findings. *Pak Vet J*, (2014); 34(4): 541-544.
- 24-Misk TN. Thoracocentesis for Diagnosis of Traumatic Pericarditis and Diaphragmatic Hernia in Cattle and Buffaloes. *Assiut Vet. Med. J.* (2015); 61(145): 70-74.
- 25-Sabev SP, Kanakov DT. Diaphragmatic Hernia in a Horse - A Case Report. *Veterinarski Arhiv*, (2009); 79 (1), 97-103.
- 26-Hendrickson DA, Suzanne ET. Large Animal Inguinal Hernia Repair. In *Veterinary Laparoscopic Surgery*. Ch. (2005); 7, PP: 237-240.
- 27-Sarker NC, Hashim MA, Ray BP. Effect of Sedative Techniques on Physiological Parameters of Calves at (Minor Surgical Procedures) L or Hernioraphy. *The Journal Of Agricultural Sciences*, (2012); 7 (2) 66-75.
- 28-Pascual G, Rodríguez M, Pérez-Köhler B, Mesa-Ciller C, Fernández-Gutiérrez M, San Román J, Bellón JM. Host Tissue Response by the Expression of Collagen to Cyanoacrylate Adhesives Used In Implant Fixation for Abdominal Hernia Repair. *J Mater Sci Mater Med.* (2017); 28(4):58.

- 29-Nevler A, Gutman M, Lebedyev A. Assessment of Gel-Coated Delayed Self-Gripping Mesh. *JSL.S.* ; (2014); 18(4).
- 30-Cornwell KG, Zhang F, Lineaweaver W. Bovine Fetal Collagen Reinforcement in a Small Animal Model of Hernia with Component Repair. *J Surg Res. Apr*; (2016); 201(2):416-424.
- 31-Morresey PR (2014). Umbilical Problems. *AAEP Focus On The First Year Of Life Proceedings*.
- 32-Kimeli P, Kipyegon AN, Mwangi WE, Mogoa EGM, Karanja DN. Diffuse Peritonitis Associated With Ventral Hernia In An Adult Doe: Case Report. *IOSR Journal of Agriculture and Veterinary Science*. (2014); 7 (1) 53-55.
- 33-Bittner R, Bingener-Casey J, Dietz U, Fabian M, Ferzli G, Fortelny R, Kočkerling F, Kukleta J, Leblanc K, Lomanto D, Misra M, Morales-Conde S, Ramshaw B, Reinhold W, Rim S, Rohr M, Schrittwieser R, Simon Th, Smietanski M, Stechemesser B, Timoney M, Chowbey P. Guidelines For Laparoscopic Treatment Of Ventral And Incisional Abdominal Wall Hernias (International Endohernia Society (IEHS). *Surg Endosc* (2014); 28:380-404.
- 34-Gurrado A, Franco IF, Lissidini G, Greco G, De Fazio M, Pasculli A, Girardi A, Piccinni G, Memeo V, Testini M. Impact Of Pericardium Bovine Patch (Tutomesh®) On Incisional Hernia Treatment In Contaminated Or Potentially Contaminated Fields: Retrospective Comparative Study. *Hernia*. (2015); 19(2):259-66.
- 35-Mendoza FJ, Perez-Ecija A, Estepa JC. Inguinal-Scrotal Herniation and Torsion Of The Large Colon In An Adult Andalusian Stallion: A Case Report. *Veterinarni Medicina*, (2010); (6): 281-284.
- 36-Salciccia A, Rebière De Pouyade G, Ponthier J, Cerri S, Parrilla-Hernandez S, Grulke S. Use Of An Automatic Stapling Device During Castration To Prevent (Re)Occurrence Of Inguinal Hernia In Horses With Large Vaginal Rings. *Journal of Equine Veterinary Science* (2014); (34): 99 -100.
- 37-Ewoldt JM. Surgery of the scrotum. *Vet Clin North Am Food Anim. Pract.* (2008); 24(2):253-266.
- 38-Al-Sobayil FA, Ahmed AF. Surgical treatment for different forms of hernias in sheep and goats. *J. Vet. Sci.* (2007); 8(2): 185-191.
- 39-Radišić B, Capak D, Matičić D, Harapin I, Kos J, Babić T, Nedeljković G. Surgical Treatment Of A Unilateral Scrotal Hernia In A Ram- A Case Report. *Veterinarski Arhiv* (2010); 80 (1) 145-154.

